

# Intestinal Mucositis Induced by 5- Fluorouracil and the Possible Protective Effect of Probiotics Containing Lactobacillus in Adult Male Albino Rats: Histological and Immunohistochemical Study

Nehal F. Shaheen, Hend R. Mousa

Department of Anatomy and Embryology, Benha faculty of medicine, Benha University, Egypt.

**Correspondence to:** Nehal F. Shaheen, Department of Anatomy and Embryology, Benha faculty of medicine, Benha University, Egypt.

**Email:**

nihal.yassine@fmed.bu.edu.eg

**Accepted:** 18 September 2022

## Abstract

**Introduction:** Intestinal mucositis is the most prevalent side effect of antineoplastic drug 5-fluorouracil (5-FU). Probiotics are live microorganisms that improve intestinal immune regulation. So, probiotics might have a beneficial effect to reduce the chemotherapy-induced enterotoxicity. **Aim:** This study aimed to assess mucositis induced by 5-FU and the possible protective effect of probiotics. **Methods:** 50 healthy albino adult male rats were divided into five equivalent groups. Control group, probiotic group was given 100  $\mu$ L of suspension containing  $1 \times 10^7$  (CFU) of probiotic cocktail daily for 9 days, 5-FU group was received 50 mg/kg of 5-FU by intraperitoneal (IP) injection once daily for 5 consecutive days, probiotic plus 5-FU group was given 50 mg/kg of 5-FU by IP injection for 5 consecutive days with probiotic cocktail once daily for 9 consecutive days and recovery group was received 50 mg/kg 5-FU by IP injection once daily for 5 consecutive days then left without medication till rats had been sacrificed on 9th day. The intestinal tissues have been prepared for a light microscopic study. **Results:** Rats of 5-FU group showed broadening, fusion and sloughing of villi into lumen, ulcerations, inflammatory infiltration, marked depletion of goblet cells, strong iNOS, marked caspase 3 and weak Ki-67 immuno-expressions. Rats treated with 5-FU plus probiotic showed preservation of normal intestinal architecture with improvement of histological and immune-histological features of mucositis. Rats of recovery group showed decrease histological and immune-histochemical features of mucositis. **Conclusion:** oral intake of the probiotic could protect against 5-FU induced intestinal mucositis in a rat model.

**Keywords:** 5-fluorouracil, probiotic, mucositis

## Introduction

Gastrointestinal toxicity due to chemotherapeutic drugs is a major cause of morbidity and mortality in cancer patients. Diarrhea, abdominal pain, nausea, vomiting and anorexia, weight loss are the most significant signs of entero-toxicity (1).

5-Fluorouracil (5-FU) is a chemotherapeutic agent commonly used for cancer therapy, mainly metastatic colorectal cancer (2,3). Intestinal mucositis is the most prevalent side effect of 5-FU therapy (4). 5-Fluorouracil is an analog of uracil and thymine. It is metabolized in the liver, generating metabolites which inhibits thymidylate synthase enzyme which is DNA synthesis and cell division (5). The cytotoxic effects of 5-FU in the GIT cells are a severe problem, as they decrease the patient's ability to tolerate treatment with discontinuation of therapy (6).

Probiotics are live microorganisms that can maintain a beneficial microbial balance in the digestive tract (7). They can be found in yogurt and other fermented foods, dietary supplements, and certain drugs (8). Probiotics have the ability to optimize the intestinal microbiota composition, improve intestinal immune regulation, and suppress oxidative stress (9,10).

Recently, probiotics have been investigated as a therapeutic approach in diarrhea, colitis, enteric infection, irritable bowel syndrome, radiation and chemotherapy-induced mucositis (11). It has been reported that probiotics can promote crypt cell proliferation, preventing apoptosis, reduce pro-inflammatory cytokine production and regulate the intestinal immune system (12).

## Material and methods

### Animals:

This experimental study was done on 50 healthy adult male albino rats weighing 180-200 gram. The rats were obtained from Faculty of Veterinary Medicine, Benha University then housed in plastic cages at  $20 \pm 2^{\circ}\text{C}$  and 14 h: 10 h light: dark, Rats were fed standard diet and water. The procedures were reviewed and approved by the Research Ethical Committee of Faculty of Medicine, Benha University. After an accommodation period of 1 week, experiment was done from 5 may 2022 to 13 may 2022.

### Drugs:

**5-Fluorouracil:** produced by Biosyn, Arzneimittel, GmbH, Germany with its trade name; 5-FU biosyn. It is presented in ampoule formula, in a concentration of 1000 mg/20 mL of 5-FU.

**Probiotic:** Lacteol fort, it was obtained from the Tenth of Ramadan Co., Egypt in the form of powder. Every sachet comprises of Lactobacillus LB (10 billion lactobacillus delbruekii and lactobacillus fermentum). The content of sachet was dissolved in sterile saline to form suspension comprising of  $1 \times 10^7$  colony forming unit (CFU) of the probiotic cocktail.

### **Experimental design**

Rats were divided randomly into 5 equal groups:

**Group I (control group):** Ten rats that were given standard diet and distilled water only.

**Group II (Probiotic group):** Ten rats, each rat was given 100  $\mu$ L of the probiotic cocktail suspension including  $1 \times 10^7$  (CFU) daily by gastric tube for 9 consecutive days (13).

**Group III ( 5-FU group):** Ten rats each received intraperitoneal injection of 50 mg/kg b.w. 5-FU once daily for 5 consecutive days from the 1<sup>st</sup> day of the experiment till the rats were sacrificed at the 5<sup>th</sup> day (14).

**Group IV (Probiotic plus 5-FU group):** Ten rats each received intraperitoneal injection of 50 mg/kg b.w. 5-FU once daily (from 1st day to 5th day) plus 100  $\mu$ L of the probiotic cocktail suspension including  $1 \times 10^7$  (CFU) by gastric tube daily for 9 consecutive days of the experiment.

**Group V (Recovery group):** Ten rats each received intraperitoneal injection of 50 mg/kg b.w. 5-FU once daily for 5 consecutive days then left without any medication till rats had been sacrificed at the 9th day the rats (15).

The rats were weighted every day during the duration of the experiment.

### **Histological examinations:**

At the end of the experiment according to timing mentioned in each group, the rats were anesthetized via intraperitoneal injection of sodium pentobarbital (Nembutal, 30 mg/kg b.w.) for sacrificing. Jejunum samples have been prepared for a light microscopic study. They were fixed in 10 % formalin for 1 day and were handled to make paraffin sections at 5  $\mu$ m thickness. The sections were stained with:

- **Hematoxylin and Eosin (H&E)** in each group to demonstrate the general histological structure (16).

- **Alcian blue stain** tissue sections were deparaffinized, soaked in distilled water, kept in 3% glacial acetic acid solution for 3 min., then incubated in Alcian-blue stain (1% Alcian blue in 3% glacial acetic acid; pH 2.5) for 30 min. Sections were counter stained with Nuclear Fast Red for 5 min, soaked in water and dehydrated (17).

### **Immunohistochemical analysis:**

To evaluate the parameters of inflammation, apoptosis and proliferation; inducible nitric oxide synthase (iNOS), cleaved caspase -3, and Ki 67 expression in the intestine were assessed by immunohistochemical staining. Formalin-fixed, paraffin-embedded tissues were cut into 4  $\mu$ m thick sections. Cell multiplying were determined after stimulation with HistoVT One, using polyclonal rabbit iNOS antibody, rabbit-raised anti-cleaved caspase-3, and anti-Ki-67 antibodies, respectively. After activation with HistoVT One, the immunocomplex was visualized by the avidin-biotin-peroxidase method using the Vecstatin Elite ABC Rabbit IgG kit, according to the manufacturer's instructions. Sections were counter-stained with haematoxylin (16,18).

### **6-Morphometrical study:**

Photographs were obtained by an Olympus IX51 light microscope equipped with a DP72 device camera. The area percent of iNOS, Caspase-3 and ki-67 immunopositive reaction at a magnification of X 200, X200 and X400 respectively and the number goblet cells at a magnification of X100 were studied in 6 non overlapping fields/slide for each group using

Leica Qwin 500 image analyser computer system (Cambridge, UK).

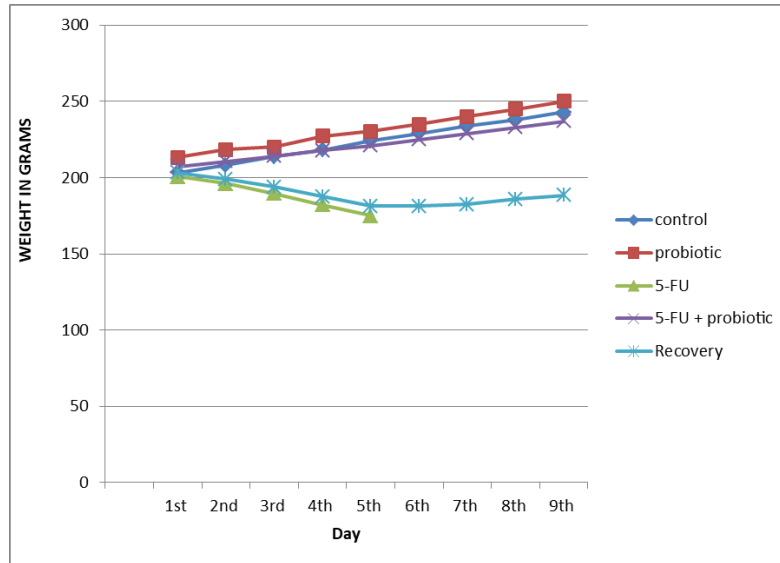
### **Statistical analysis**

Data were expressed as mean  $\pm$  SD.  $p \leq 0.05$  was significant tested by using one-way analysis of variance (ANOVA) and post hoc multiple comparisons by using SPSS software (v.16; Chicago, USA).

### **Results:**

#### **Weight measurement results:**

The measurements of the mean body weight of the rats of all groups presented in histogram 1. Rats of control and probiotic groups showed a progressive increase in mean body weight during all days of experiment. Rats of 5-FU group showed significant loss of mean body weight, when compared to initial weight recorded on 1st day of 5-FU injection of this group. Probiotic suppressed body weight loss induced by 5-FU. The mean body weight of rats of the recovery group in the first days was significantly decreased, after stoppage of 5-FU injection there was an increase in body weight; however, the mean body weight stayed significantly lesser than that of the control.



**Histogram (1):** Showing mean body weight of rats in the 5 groups

**Histological result:**

**H &E stain:**

Sections of intestine of rats stained with H&E of probiotic group didn't reveal any difference from control group.

**Group I & II:** Sections stained with H&E of intestine of control and probiotic groups revealed that the mucosa of jejunum showed villi and crypts. The villi appeared as finger like projections thrown into the lumen. The crypts of Lieberkuhn appeared as tube like structures opened between the bases of the villi and extended deeply to the muscularis mucosa (Fig 1a,1b ). The surface of the villi was covered by absorptive cells which appeared tall columnar cells with basal oval nuclei. The goblet cells were scattered between the absorptive cells (Figs 2a,2b).

Paneth cells in the base of crypts, appeared as pyramidal cells with basal rounded nuclei and apical eosinophilic secretory granules (Figs 3a, 3b).

**Group III:** Sections stained with H&E of intestine of rats of 5-FU group showed loss of normal jejunal architecture varying from broadening, fusion of some villi up to sloughing into the lumen and areas of complete erosion of the mucosa. The lamina propria was separated from absorptive epithelium and infiltrated with inflammatory cells (Fig.1c, 1d). The absorptive cells covering the villi were multi-nucleated with cubical or rounded nuclei. The surface epithelium of the villi showed sporadic areas of erosion. Lamina propria contained

extravasation of RBCs and sub-epithelial vacuolation. (Fig.2c). Some paneth cells appeared ballooned with increase in their apical eosinophilic granules and others were destructed. The lamina propria showed vacuolations and inflammatory infiltration. The mucosa was detached from underlying muscularis mucosa (Fig.3c).

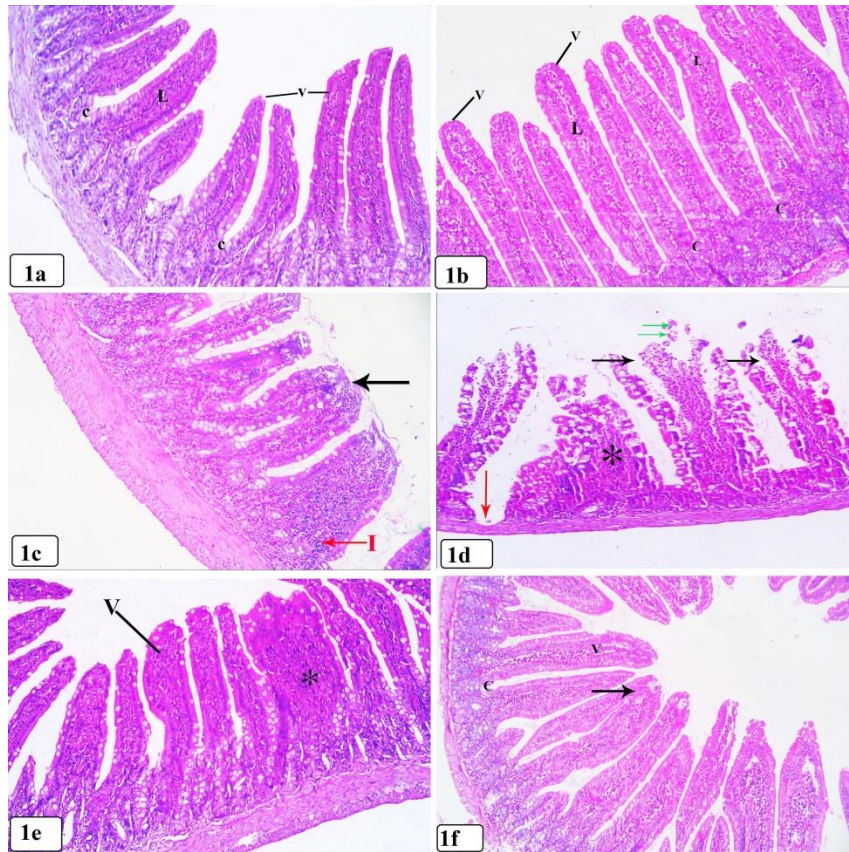
#### **Group IV:**

Sections stained with H&E of intestine of rats treated with 5-FU plus probiotic showed preservation of normal jejunal architecture with broadening of some villi (Fig.1e).Some absorptive cells covering the villi appeared tall columnar cells with basal oval nuclei in some villi and other villi appeared cubical multinucleated (Fig 2d) .The intestinal crypts lined with normal absorptive cells and goblet cells. At its bottom, paneth cells appeared pyramidal in shape with basal rounded nucleus. The lamina propria surrounding

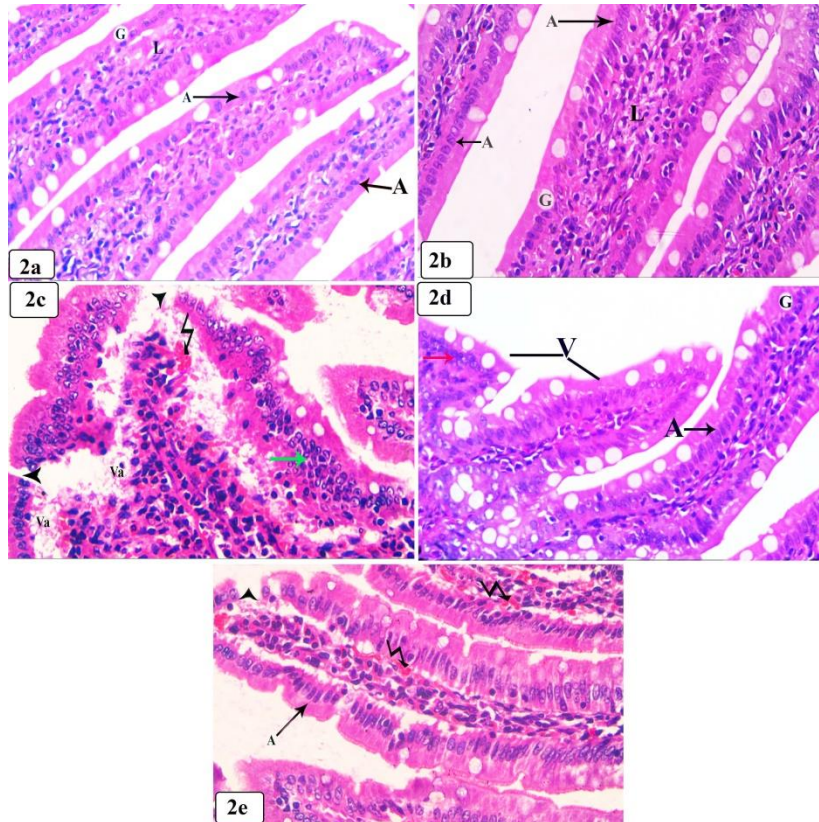
crypts showed inflammatory infiltration (Fig.3d).

#### **Group V:**

Sections stained with H&E of intestine of rats of the recovery group showed return of normal jejunal architecture of the mucosa but some villi were joined (Fig.1f). The absorptive cells covering the villi appeared tall columnar cells with basal oval nuclei in some villi and other villi appeared cubical multinucleated. The covering epithelium was intact in some areas, while in other areas was destructed. The lamina propria showed extravasation of RBCs (Fig.2e). Some paneth cells appeared pyramidal in shape with basal rounded nucleus and apical secretory granules and some appear ballooned. Rounded cystic configuration containing cellular debris replaced the normal structure of the crypts. (Fig. 3e)

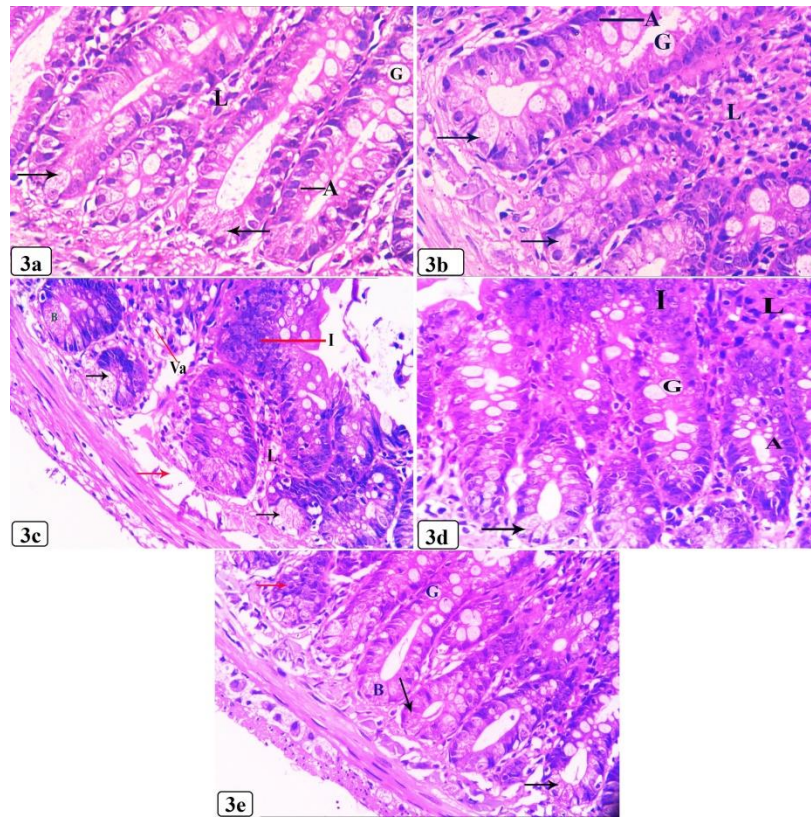


**Fig (1):** A light micrographs of transverse section (T.S) in rat jejunum: **(1a)** group I and **(1b)** group II: showing lining mucosa of jejunum has tongue like projections called villi (v) and a core of connective tissue called lamina propria (L), crypts of Lieberkuhn (C). **(1c)** group III showing: fusion of some villi (black arrow) and broadening of villi with The lamina propria is infiltrated with inflammatory cells (I). **(1d)** group III showing : Sloughing of the villi into the lumen(green arrow) and broadening of villi(asterisk).The lamina propria is separated from absorptive epithelium(black arrow). complete erosion of the mucosa(red arrow). **(1e)** group IV showing: normal jejunal architecture (V) with broadening of some villi (asterisk). **(1f)** group V showing: normal jejunal architecture of the mucosa (V) but some villi are joined (arrow). (H&E X100)



**Fig (2):** A light micrograph of T.S in rat jejunum: **(2a)** group I and **(2b)** group II: showing the villi are covered by absorptive cells (A) with their cubical basal nuclei and mature goblet cells (G) lamina propria (L). **(2c)** group III: showing intestinal villi with its covering absorptive cells are multinucleated with cubical or round nuclei (green arrow). Sporadic areas of discontinuity of absorptive epithelium (head arrow). subepithelial vacuolation (va) and extravasation of RBCs (zigzag line). **(2d)** group IV: Some absorptive cells covering the villi (V) appeared columnar cells with basal oval nuclei (A) and other absorptive cells appeared cubical multinucleated (red arrow). **(2e)** group V showing: covering cells appear tall columnar cells (A) with basal oval nuclei. sporadic areas of discontinuity (head arrow). Lamina propria shows extravasation of RBCs (zigzag line). (H&E X 400)



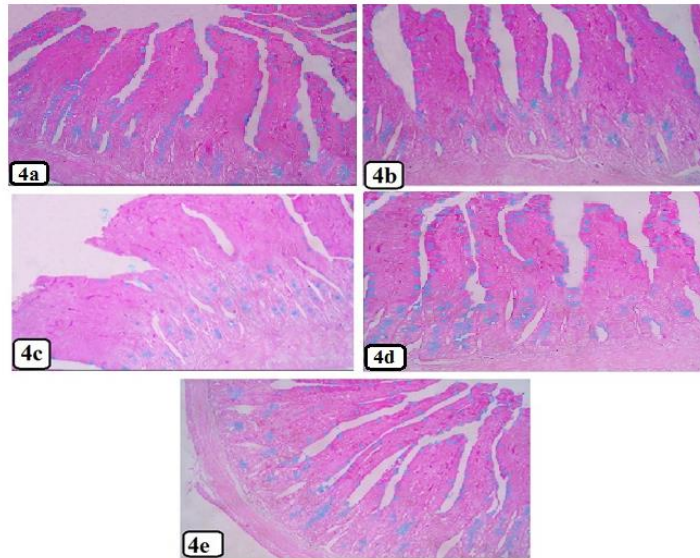


**Fig ( 3):** A light micrograph of T.S in rat jejunum: **(3a)** of group I,**(3b)** of group II showing crypts of Lieberkuhn surrounded by lamina propria (L) and are lined with absorptive cells (A) and immature goblet cells (G) paneth cells (arrow) which appear as pyramidal cells with basal rounded nuclei and apical eosinophilic secretory granules.**(3c)** Group III showing some paneth cells are degenerated (black arrow) and others appeared ballooned with increase in their apical eosinophilic granules (B). The lamina propria (L) showed vacuolation (va) and inflammatory infiltration (I). Detached mucosa (red arrow).**(3d)** group IV showing: The intestinal crypts lined with normal absorptive cells (A) and goblet cells (G). Paneth cells are pyramidal in shape with basal rounded nucleus (black arrow). Inflammatory cells infiltration of lamina propria (I). **(3e)** group V showing: The intestinal crypts lined with normal absorptive cells (A) and goblet cells (G). Paneth cells are pyramidal in shape with basal rounded nucleus (black arrow) and some appeared ballooned (B). Some crypts appeared rounded cystic configuration containing cellular debris (red arrow) . **(H&E X 400 )**

### Alcian blue stain:

Sections stained with Alcian blue of group I **(4a)** and group II **(4b)** showed the goblet cells containing acid mucin appeared turquoise-blue in color and scattered along villi and crypts . group III showed marked depletion of

the goblet cells in the villi and aggregations in the crypts **(4c)**. Group IV showed preservation of the number of goblet cells **(4d)**. Group V showed increase of the number of goblet cells **(4e)**.

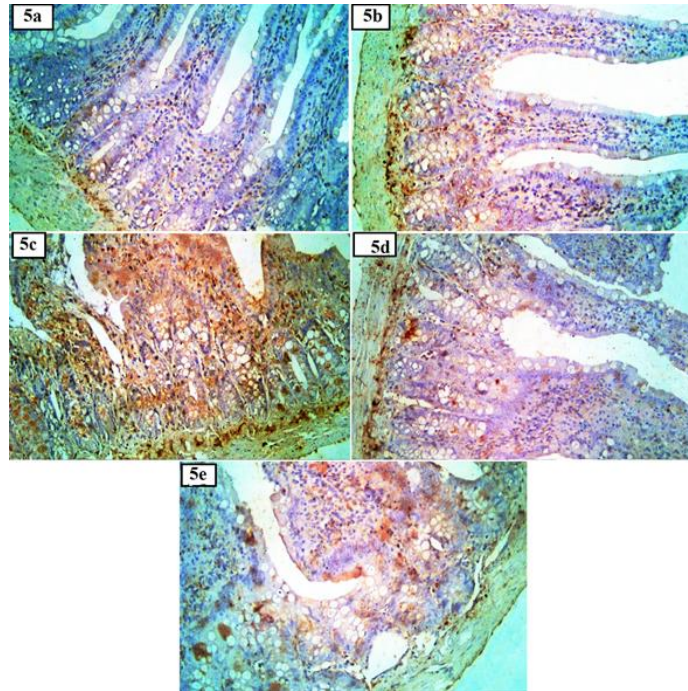


**Fig (4):** Light micrographs of T.S in rats jejunum : **(4a)** group I & **(4b)** group II showing: goblet cells containing acid mucin scattered all over villi and crypts.**(4c)** group III showing: marked depletion of goblet cells in villi and its aggregations in the crypts. **(4d)** group IV & **(4e)** group V showing: goblet cells scattered all over villi and crypts. (Alcian blue X 100).

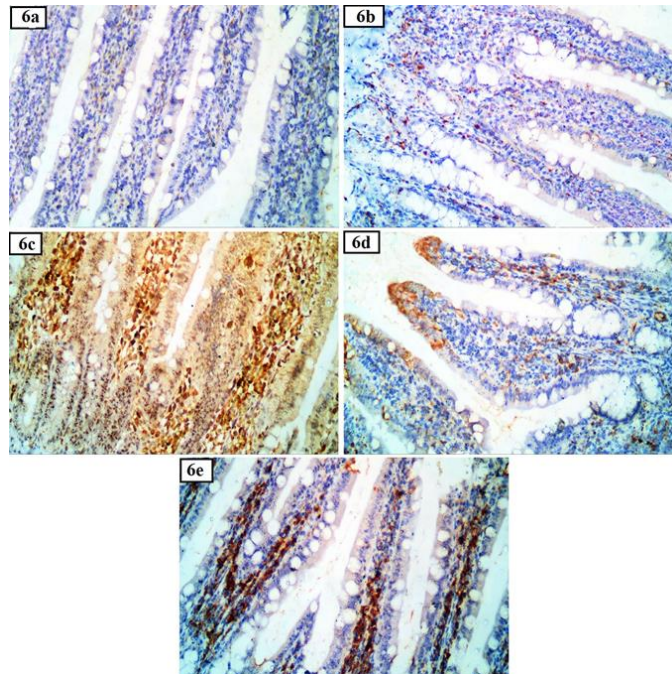
### **Immunohistochemical findings**

Immunostaining of rat intestine using iNOS antibody (Figure 5). Small intestine of I & II groups showed negative iNOS immunoexpression. Group III showed intense iNOS immunoexpression in the cells of lamina propria of villi and crypts. Group IV showed minimal iNOS immunoexpression. Group V showed less marked iNOS immunoexpression. Immunostaining of rat intestine using caspase- 3 antibody (Figure 6). Both control and probiotic groups showed negative caspase- 3 expression, while group

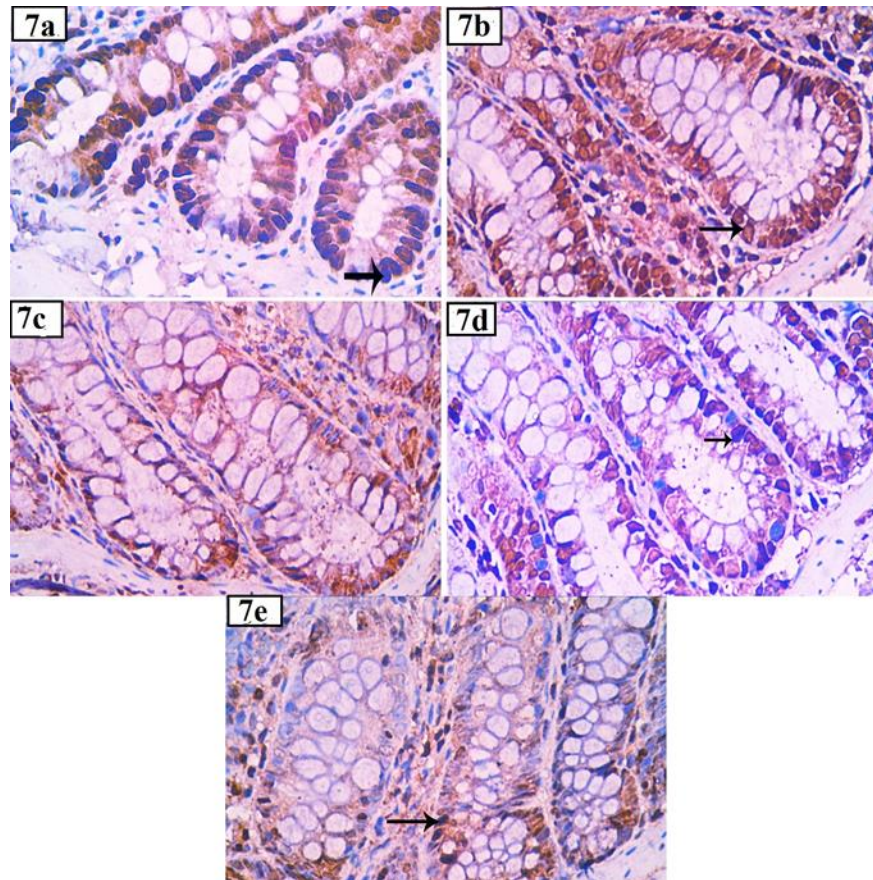
III showed intense caspase 3 expression in the villi and crypts. Group IV showed minimal caspase -3 expression. Group V showed less marked caspase -3 expression in the lamina propria of the villi. Immunostaining of rat intestine using Ki-67 antibody (Figure 7). Small intestine of control and probiotic group showed intense immunoexpression in the cell lining the crypts. While, group III showed weak Ki-67 immunoexpression. Group IV showed marked Ki-67 immunoexpression. Group V showed moderate Ki-67 antibody immunoreactions.



**Fig (5)** An immunostained photomicrograph of rat intestine using iNOS. Small intestine of group I (**5a**) and group II (**5b**) showing: negative iNOS immuno-expression. Group III (**5c**) showing: intense iNOS immuno-expression in the cells of lamina propria of villi and crypts regions. Group IV (**5d**) showing: minimal iNOS immuno-expression. Group V (**5e**): showing less marked iNOS immuno-expression. (iNOS x 200)



**Fig (6)** An immunostained photomicrograph of rat intestine using caspase -3 antibody. Both group I (**6a**) and group II (**6b**) showing: negative caspase -3 expressions. Group III (**6c**) showing: intense caspase -3 expressions in the villi and crypts. (**6d**) group IV showing: minimal caspase -3 expression. (**6e**) group V showing: less marked caspase- 3 expression in the lamina propria (Caspase-3x200).



**Fig (7)** An immunostained photomicrograph of rat intestine using Ki-67 antibody. The cell lining the crypts of jejunum of group I (7a) and group II (7 b) showing: intense Ki-67 immunoreexpression, while group III (7c) showing: weak immunoreactions. Group IV (7d) showing: marked Ki-67 immunoreexpression. Group V (7e) showing: moderate Ki-67 immunoreexpression. (Ki-67X 400)

### Morphometric results

Both control and probiotic groups had the same results and there weren't any significant difference between them in all parameters. The mean area (%) of number of goblet cells stained by alcian blue sections represented in table (1). In group III, there was a significant decrease in area % of number of goblet cells stained by alcian blue sections in comparison with control group ( $P \leq 0.05$ ). In

IV and V groups, there were significant increase in area % of number of goblet cells in comparison with III and significant decrease in comparison with control group ( $P \leq 0.05$ ). The mean area % of iNOS immunoreactivity was represented in table (2). In group III, there was a significant increase in area % of iNOS immunoreactivity in comparison with control group ( $P \leq 0.05$ ). In IV and V groups, there

were significant decrease in area % of iNOS immunoreactivity in comparison with III ( $P \leq 0.05$ ) but there were in a significant increase in comparison with control group ( $P \leq 0.05$ ).

The mean area % of caspase 3 immunoreactivity was represented in table (3). In group III, there was a significant increase in area % of caspase 3 immunoreactivity in comparison with control group ( $P \leq 0.05$ ). In IV and V groups, there were significant decrease in area % of caspase 3 immunoreactivity in comparison with III ( $P \leq 0.05$ ). In group IV, there was no significant difference in comparison with control group

( $P \leq 0.05$ ) but in group V, there was significant increase in comparison with control group ( $P \leq 0.05$ ).

The mean area % of ki-67 immunoreactivity for was represented in table (5). In group III, there was a significant decrease in area % of ki-67 immunoreactivity in comparison with control group ( $P \leq 0.05$ ). In group IV, there was significant increases in area % of ki-67 immunoreactivity in comparison with III ( $P \leq 0.05$ ). In group V, there was significant decrease in area % of ki-67 immunoreactivity in comparison with control group and group IV ( $P \leq 0.05$ ).

**Table (1):** showing mean values of goblet cells number  $\pm$  SD in the 5 experimental groups.

Mean $\pm$ SD	control group I	Probiotic group II	5-FU treated Group III	5-FU plus probiotic group IV	Recovery Group V
Goblet number	261 $\pm$ 8.7	263 $\pm$ 13.07	109 $\pm$ 7.02	229 $\pm$ 8.5	184 $\pm$ 7.3
Significance 0.05	$\leq$ With groups III, IV & V	With groups III, IV & V	With groups I, II, IV & V	With groups I, II, III & V	With groups I, II, III & IV

**Table (2):** showing mean values of area % immunoreactivity of iNOs  $\pm$  SD in the 5 groups

Mean % $\pm$ SD	control group I	probiotic group II	5-FU treated Group III	5-FU plus probiotic group IV	Recovery Group V
iNOs	4.74 $\pm$ 1.7	3.82 $\pm$ 2.2	35.94 $\pm$ 3.8	13.02 $\pm$ 2.02	15.7 $\pm$ 2.3
Significance $\leq$ 0.05	With groups III, IV & V	With groups III, IV & V	With groups I, II, IV & V	With groups I, II & III	With groups I, II & III

**Table (3):** showing the mean values of area % immunoreactivity of caspase  $\pm$  SD in the 5 groups.

Mean $\pm$ SD	control group I	Probiotic group II	5-FU treated Group III	5-FU plus probiotic group IV	Recovery Group V
caspase	6.26 $\pm$ 1.26	5.96 $\pm$ 1.4	30.1 $\pm$ 2.8	11.16 $\pm$ 3.18	15.24 $\pm$ 2.2
Significance $\leq$ 0.05	With groups III &V	With groups III&V	With groups I,II,IV & V	With group III	With groups I, II & III

**Table (4) :**showing the mean values of area % immunoreactivity of Ki-67  $\pm$  SD in the 5 groups.

Mean % $\pm$ SD	control Group I	Probiotic Group II	5-FU treated Group III	5-FU plus probiotic Group IV	Recovery Group V
Ki-67	35.48 $\pm$ 5.4	34.82 $\pm$ 3.1	5.49 $\pm$ 1.9	30.49 $\pm$ 9.18	10.42 $\pm$ 0.75
Significance $\leq$ 0.05	With groups III &V	With groups III&V	With groups I,II & IV	With groups III & V	With groups I, II & IV

## Discussion:

5-fluorouracil (5-FU) is an anticancer therapy, as one of its metabolites is an inhibitor of thymidylate synthase which is critical in DNA replication [6]. The GIT mucosa in addition to having an absorptive role, it acts as a physical and immunological barrier. [19,20] Many studies have confirmed that the injury of intestinal mucosal caused by 5-FU- harms the intestinal barrier resulting in invasion of the gut flora into the circulation that lead to systemic inflammatory response [21].

The present study has been performed to assess the histological and immune-

histochemical features of 5-FU induced cytotoxicity on the rat jejunum and to investigate the possible protective effect of probiotics to prevent this cytotoxicity.

In the present study, rats of the 5-FU group showed progressive body weight loss from the second day after 5-FU injection. The same finding was reported before in methotrexate and 5-FU treated rats [22,23,24]. Other authors assumed the cause of body loss is diarrhea and changed intestinal absorptive capacity [25]. The treatment of probiotic with 5-FU in our study

was able to reduce weight loss significantly, the same as De Jesus et al.,<sup>[26]</sup>.

In the present study, histological features of mucositis following 5-FU administration were represented by loss of intestinal architecture, exfoliation, fusion, broadening of villi, erosions of epithelium and sub-epithelial vacuolation. Similar findings were reported by De Jesus et al.,<sup>[26]</sup> and Koizumi et al.,<sup>[27]</sup>

In this study, the lamina propria was detached from absorptive epithelium covering the villi and showed empty spaces and extravasation of RBCs. These findings were similar to finding of Gawish et al.,<sup>[15]</sup>. The mucosal damage in the present study was found to progress up to complete erosion of the mucosa. This was in agreement with other authors<sup>[28,29,30]</sup>.

In this study, intense inflammatory cell infiltration was seen in the lamina propria in rats treated with 5-FU, the same finding as Gawish et al.,<sup>[15]</sup>. Cellular inflammatory infiltration in the lamina propria in 5-FU treated rat is subsequent to increase concentrations of the pro-inflammatory cytokines (T-NF  $\alpha$  and IL- 6,) in the intestinal tissue<sup>[6]</sup>. Neutrophils are the first cells that arrive at the site of mucositis, and they release myeloperoxidase (MPO) in the first hours after 5-FU administration<sup>[23, 29]</sup>.

Mucositis is initiated by 5-FU by decreasing antioxidant glutathione (GSH) and increasing extracellular release of MPO which produces reactive oxygen species (ROS) that cause intestinal oxidative damage<sup>[31]</sup>. Another study on the effect of 5-FU on jejunum of rats concluded that it increased level of malondialdehyde (MDA) and up regulated of NF- $\kappa$ B signaling pathway within the jejunum, this caused disturbance of gut epithelial barrier<sup>[1,32,33]</sup>.

Paneth cell is one of stem cells in intestine and has an important role in intrinsic mucosal immunity<sup>[34]</sup>. In this study, 5-FU harmed paneth cells which appeared either ballooned or completely damaged. This was in the harmony with other studies that recorded an increase of apoptotic index in stem cells of intestinal crypts after 5-FU treatment<sup>[35, 36]</sup>. Other authors found no notable differences in the number of the paneth cells in chemotherapy induced mucositis but in electron microscopic examination of paneth cells, the endoplasmic reticulum was disturbed and decrease mRNA levels of lysozyme<sup>[37]</sup>.

In this study, the probiotic was capable of preventing intestinal epithelial damage induced by 5-FU, these results were the same as Oh et al.,<sup>[38]</sup> and Bastos et al.,<sup>[39]</sup>. Probiotics can preserve the cellular junctions

and reduce the paracellular permeability by modifying the gene expression of tight junction proteins<sup>[40]</sup>.

Probiotic mixture could suppress oxidative stress by reducing MDA and MPO activities<sup>[41]</sup>. Probiotics reduced the over-activation of the NF- $\kappa$ B signaling pathway by inhibition of expression of TNF- $\alpha$  and IL-6 levels in small intestine to relieve intestinal inflammation<sup>[42,43, 44]</sup>. Intake of probiotic in patients treated with chemotherapy showed marked lessening of serum pro-inflammatory cytokines; TNF- $\alpha$  and IL-6 demonstrating an immune-regulatory capability of Probiotic<sup>[45]</sup>.

Mucin secreted by goblet cells is the most important factor for the protection of the epithelium, migration of goblet cells to the villi is representing a cell renewal<sup>[46]</sup>. Our results showed that the number of goblet cells dramatically diminished in 5-FU treated rat. However, rats treated with 5-FU plus probiotic showed significantly higher goblet cell numbers. This was the same as reported by Yeung et al.,<sup>[24]</sup> and Ciobanu et al.,<sup>[47]</sup>.

In this study, the expression of iNOS immunostaining increased following treatment with 5-FU, it was particularly observed in lamina propria cells and the cell lining of the crypt. While, probiotic treatment with 5-FU reduced the high iNOS expression. These

finding were similar to Costa et al.,<sup>[32]</sup> and Leitão et al.,<sup>[48]</sup>.

In the present study, the administration of 5-FU led to increase expression of caspase-3 in intestinal villi, this finding was similar to those of Ji et al.,<sup>[6]</sup> and De Barros et al.,<sup>[49]</sup>. This was abolished by daily administration of probiotic plus 5-FU, this was in concurrence with An et al.<sup>[50]</sup>. Other authors found that Probiotic down-regulated the increased expression of cleaved caspase-3 expression via p38-mediated autophagy<sup>[51]</sup>.

In this study, the expression of Ki-67 nuclear protein showed marked reduction in the intestinal crypts of rats that received doses of 5-FU in contrary when probiotic was administrated with 5-FU, as the nuclear expression of Ki-67 was increased. This was the same as De Ávila et al.,<sup>[52]</sup>.

In the present study, signs of intestinal auto-recovery demonstrated in recovery group like diminution of body weight loss, diminution in histological features of mucositis. There were rise in goblet cell number, decrease in iNOS and caspase-3 immuno-expression and increase Ki-67 immuno-expression but in significant differences with control group so, it wasn't considered as complete recovery. Other investigators stated that the initial recovery



occurred by increase in crypt depth and mitotic count 6 days after single injection of 5-FU [15]. Another study indicated that the structure and absorptive function of the villi can return to normal after around 1 week from the onset of chemotherapy [53]. Crypt renewal varies according to time of drug exposure, doses, route of administration and type of chemotherapy [54].

### Conclusion:

Oral intake of the probiotic could protect against 5-FU induced intestinal mucositis in a rat model.

### References:

- 1- Lee CS, Ryan EJ, Doherty GA. Gastro-intestinal toxicity of chemotherapeutics in colorectal cancer: the role of inflammation. *World J.Gastroenterol.* 2014; 20:3751–3761.
- 2- Vodenkova S, Buchler T, Cervena K, Veskrnova V, Vodicka P, Vymetalkova V. 5-fluorouracil and other fluoropyrimidines in colorectal cancer: Past, present and future. *Pharmacol Ther.* 2020; 206:107447.
- 3- De Miranda JAL, Martins CDS, Fideles LS, Barbosa MLL, Barreto JEF, Pimenta HB, et al. Troxerutin Prevents 5-Fluorouracil Induced Morphological Changes in the Intestinal Mucosa: Role of Cyclooxygenase-2 Pathway. *Pharmaceuticals (Basel).* 2020;13(1):10
- 4- Kim HJ, Kim JH, Moon W, Park J, Park SJ, Song GA, et al. Rebamipide Attenuates 5-Fluorouracil-Induced Small Intestinal Mucositis in a Mouse Model. *Biol. Pharm. Bull.* 2015; 38 179–183.
- 5- Justino PFC, Franco AX, Pontier-Bres R, Monteiro CES, Barbosa ALR, Souza MHL P, et al. Modulation of 5-fluorouracil activation of tolllike/MyD88/NF-κB/MAPK pathway by *Saccharomyces boulardii* CNCM I-745 probiotic. *Cytokine.* 2020;125:154791.
- 6- Ji Y, Zhou W, Tan W, Chen Z, Lu H, You Y, et al. Protective effect of polysaccharides isolated from the seeds of *Cuscuta chinensis* Lam. On 5-fluorouracil-induced intestinal mucositis in mice. *Acta Cir Bras.* 2022 May 2;37(2)
- 7- Maioli TU, de Melo Silva B, Dias MN, Paiva NC, Cardoso VN, Fernandes SO, et al. Pretreatment with *Saccharomyces boulardii* does not prevent the experimental mucositis in Swiss mice. *J Neg Results Biomed.* 2014;13:6.
- 8- Jacouton E, Chain F, Sokol H, Langella P, Bermudez-Humaran LG. Probiotic strain *Lactobacillus casei* BL23 prevents colitis-associated colorectal cancer. *Front. Immunol.* 2017 ; 8:1553
- 9- Yang J, Wang C, Huang K, Zhang M, Wang J, Pan X. Compound *Lactobacillus* sp. Administration ameliorates stress and body growth through gut microbiota optimization on weaning piglets. *Appl Microbiol Biotechnol.* 2020;104(15):6749–65.

- 10-Meng C, Bai C, Brown TD, Hood LE, Tian Q. Human gut microbiota and gastrointestinal cancer. *Genomics Proteomics Bioinformatics*. 2018; 16, 33–49.
- 11-Bellavia M. *Lactobacillus casei* and *Bifidobacterium lactis* supplementation reduces tissue damage of intestinal mucosa and liver after 2,4,6-trinitrobenzenesulfonic acid treatment in mice. *J Biol Regul Homeost Agents*. 2014 ;28(2):251–61.
- 12- Batista VL, da Silva TF, de Jesus LCL, Coelho-Rocha ND, Barroso FAL, Tavares LM, et al. Probiotics, Prebiotics Synbiotics, and Paraprobiotics as a Therapeutic Alternative for Intestinal Mucositis. *Front. Microbiol*. 2020; 11:544490.
- 13- Chang CW, Liu CY, Lee HC, Huang YH, Li LH, Chiau JC, et al. *Lactobacillus casei* Variety rhamnosus Probiotic Preventively Attenuates 5-Fluorouracil/Oxaliplatin-Induced Intestinal Injury in a Syngeneic Colorectal Cancer Model. *Front Microbiol*. 2018 May 15;9:983.
- 14- Hamouda N, Sano T, Oikawa Y, Ozaki T, Shimakawa M, Matsumoto K, et al. Apoptosis, dysbiosis and expression of inflammatory cytokines are sequential events in the development of 5-fluorouracil-induced intestinal mucositis in mice. *Basic Clin. Pharmacol. Toxicol*. 2017; 121(3):159–168.
- 15-Gawish SA, Nousseir DA, Omar NM, Sarhan NM. Histological and Ultra Structural Study of 5-fluorouracil-induced Small Intestinal Mucosal Damage in Rats. *Asian Journal of Cell Biology* 2013; 8(1):1-21
- 16- El-Sheikh AA, Ameen SH, AbdEl-Fatah SS. Ameliorating Iron Overload in Intestinal Tissue of Adult Male Rats: Quercetin vs Deferoxamine, *Journal of Toxicology*. 2018; vol. 2018, 13 pages
- 17- Datta K, Suman S, Kallakury BV, Fornace AJ Jr. Heavy ion radiation exposure triggered higher intestinal tumor frequency and greater  $\beta$ -catenin activation than  $\gamma$  radiation in APC(Min/+) mice. *PLoS One*. 2013;8(3):e59295.
- 18- Yasuda M, Kato S, Yamanaka N, Iimori M, Utsumi D, Kitahara Y, et al. Potential role of the NADPH oxidase NOX1 in the pathogenesis of 5-fluorouracil-induced intestinal mucositis in mice. *Am J Physiol Gastrointest Liver Physiol*. 2012;302(10):G1133-G1142
- 19- Salvo Romero E, Alonso Cotoner C, Pardo Camacho C, Casado Bedmar M, Vicario M. The intestinal barrier function and its involvement in digestive disease. *Rev Esp Enferm Dig*. 2015;107(11):686-696.
- 20- König J, Wells J, Cani PD, García-Ródenas CL, MacDonald T, Mercenier A, et al. Human intestinal barrier function in health and disease. *Clin. Transl. Gastroenterol*. 2016; 7:e196 .
- 21-Shen SR, Chen WJ, Chu HF, Wu SH Wang YR, Shen TL .Amelioration of 5 fluorouracil-induced intestinal mucositis by *Streptococcus ysteinelles* ST4 in a mouse model. *PloS One* 2021; 16(7).
- 22- Li HL, Lu L, Wang XS, Qin LY, Wang, Qiu SP, et al. Alteration of gut microbiota and

- inflammatory cytokine/chemokine profiles in 5-Fluorouracil induced intestinal mucositis. *Front Cell Infect Microbiol.* 2017;455: (7) 26.
- 23- Fideles LS, de Miranda JAL, Martins CDS, Barbosa MLL, Pimenta HB, Pimentel PVS, et al. Role of Rutin in 5-Fluorouracil-Induced Intestinal Mucositis: Prevention of Histological Damage and Reduction of Inflammation and Oxidative Stress. *Molecules.* 2020;25(12):2786.
- 24- Yeung CY, Chan WT, Jiang CB, Cheng ML, Liu CY, Chang SW, et al. Amelioration of Chemotherapy-Induced Intestinal Mucositis by Orally Administered Probiotics in a Mouse Model. *PloS ONE.* 2015; 10(10): e0141402.
- 25- Miaomiao Hu, Xiaoli Wu, Meng Luo, Hua Wei, Feng Xu, Di Xu. *Lactobacillus rhamnosus* FLRH93 protects against intestinal damage in mice induced by 5-fluorouracil. *Journal of Dairy Science.* 2020; 103(6) 5003-5018.
- 26- De Jesus LC, Drumond MM, de Carvalho AD, Santos SS, Martins FD, Ferreira Ê, et al. Protective effect of *Lactobacillus delbrueckii* subsp. *Lactis* CIDCA 133 in a model of 5 Fluorouracil-Induced intestinal mucositis. *Journal of Functional Foods.* 2019; 53 :197–207
- 27- Koizumi R, Azuma K, Izawa H, Morimoto M, Ochi K, Tsuka T, et al. Oral Administration of Surface-Deacetylated Chitin Nanofibers and Chitosan Inhibit 5-Fluorouracil-Induced Intestinal Mucositis in Mice. *Int. J. Mol. Sci.* 2017; 18, 279.
- 28- Kamar SS, Baky MH, Omar AI. The beneficial influence of rhubarb on 5-fluorouracil-induced ileal mucositis and the combined role of aquaporin-4, tumour necrosis factor- $\alpha$ , nuclear factor-kappa B & matrix metalloproteinase-9 in rat model: histological study. *Anat Cell Biol.* 2020 Jun 30;53(2):228-239.
- 29- Cinausero M, Aprile G, Ermacora P, Basile D, Vitale MG, Fanotto V, et al. New frontiers in the pathobiology and treatment of cancer regimen-related mucosal injury. *Front. Pharmacol.* 2017; 8:354.
- 30- Cereda E, Caraccia M, Caccialanza R. Probiotics and mucositis. *Curr. Opin. Clin. Nutr. Metab. Care.* 2018; 21, 399–404.
- 31- Yoneda J, Nishikawa S, Kurihara S. Oral administration of ysteine and theanine attenuates 5-fluorouracil-induced intestinal mucositis and diarrhea by suppressing both glutathione level decrease and ROS production in the small intestine of mucositis mouse model. *BMC Cancer.* 2021 Dec 18;21(1):1343.
- 32- Costa DVS, Bon-Frauches AC, Silva AMHP, Lima-Júnior RCP, Martins CS, Leitão RFC, et al. 5-Fluorouracil Induces Enteric Neuron Death and Glial Activation During Intestinal Mucositis via a S100B-RAGE-NF $\kappa$ B-Dependent Pathway. *Sci Rep.* 2019;9(1):665.
- 33- Chang CT, Ho TY, Lin H, Liang JA, Huang HC, Li CC, et al. 5-Fluorouracil Induced Intestinal Mucositis via Nuclear Factor- $\kappa$ B Activation by Transcriptomic Analysis and *In Vivo* Bioluminescence Imaging. *PloS ONE.* 2012; 7(3): e31808.
- 34- Lueschow SR, McElroy SJ. The Paneth Cell: The Curator and Defender of the Immature Small Intestine. *Front Immunol.* 2020;11:587.

- 35- Wang X, Gao J, Qian L, Gao J, Zhu S, Wu M, et al. Exogenous IL-1Ra attenuates intestinal mucositis induced by oxaliplatin and 5-fluorouracil through suppression of p53-dependent apoptosis. *Anticancer Drugs*. 2015;26(1):35-45.
- 36- Zhan Y, Xu C, Liu Z, Yang Y, Tan S, Yang Y, et al.  $\beta$ -Arrestin1 inhibits chemotherapy-induced intestinal stem cell apoptosis and mucositis. *Cell Death Dis*. 2016 May 19;7(5) :e2229.
- 37- Zuo T, He X, Cao L, Xue C, Tang Q .The dietary polysaccharide from *Ommastrephes bartrami* prevents chemotherapeutic mucositis by promoting the gene expression of antimicrobial peptides in Paneth cells ,*Journal of Functional Foods*. 2015; (12) : 530-539
- 38- Oh NS, Lee JY, Lee JM, Lee KW, Kim Y. Mulberry leaf extract fermented with *Lactobacillus acidophilus* A4 ameliorates 5-fluorouracil-induced intestinal mucositis in rats. *Lett Appl Microbiol*. 2017 Jun;64(6):459-468.
- 39- Bastos RW, Pedroso SH, Vieira AT, Moreira LM, França CS, Cartelle CT, et al. *Saccharomyces cerevisiae* UFMG A-905 treatment reduces intestinal damage in a murine model of irinotecan-induced mucositis. *Benef Microbes*. 2016;7(4):549-557.
- 40- Yu Q, Yuan L, Deng J, Yang Q. *Lactobacillus* protects the integrity of intestinal epithelial barrier damaged by pathogenic bacteria. *Front Cell Infect Microbiol*. 2015 Mar 25;5:26.
- 41- Quaresma M, Damasceno S, Monteiro C, Lima F, Mendes T, Lima M, et al. Probiotic mixture containing *Lactobacillus* spp. And *Bifidobacterium* spp. Attenuates 5-fluorouracil-induced intestinal mucositis in mice. *Nutr. Cancer*. 2019; 12 1–11
- 42- Wang L, Liu SL, Xu ZP, Song Q, Li L, Qiu ZL, et al. Protective effect of *Lactobacillus*-containing probiotics on intestinal mucosa of rats experiencing traumatic hemorrhagic shock. *Open Life Sci*. 2021;16(1):1122-1129.
- 43- Yue B, Yu Z, Luo X, Ren Y, Zhang J, Ren J, et al. Pinocembrin alleviates ulcerative colitis in mice via regulating gut microbiota, suppressing TLR4/MD2/NF-kappaB pathway and promoting intestinal barrier. *Biosci Rep*. 2020;40(7) .
- 44- Lee JH, Lee B, Lee HS, Bae EA, Lee H, Ahn YT, et al *Lactobacillus* *suntoryeus* inhibits pro-inflammatory cytokine expression and TLR-4-linked NF-kappaB activation in experimental colitis. *Int J Colorectal Dis*. 2009;24(2):231–7.
- 45- Raja ARA, Liyana Z, Seow-Neg C, Zhiqin W, Chai SN, Norfilza MM . Sa1838-The clinical and circulating inflammatory cytokines effects of probiotic containing *Lactobacillus* and *Bifidobacterium* strains in patients with colorectal cancer: a randomized double blind controlled trial. *Gastroenterology*.2018; 154(6), S-414.
- induced mucositis. *PloS Pathog*. 2010 May 27;6(5).

- 47- Ciobanu L, Tantau M, Valean S, Parau A, Bedecian I, Mîrleneanu R, et al. Rifaximin modulates 5-fluorouracil-induced gastrointestinal mucositis in rats. *European Review for Medical and Pharmacological Sciences*. 2016; 20(23), 4993–5001
- 48- Leitão RF, Brito GA, Oriá RB, Braga-Neto MB, Bellaguarda EA, Silva JV, et al. Role of inducible nitric oxide synthase pathway on methotrexate-induced intestinal mucositis in rodents. *BMC Gastroenterol*. 2011; 11, 90.
- 49- De Barros PAV, Rabelo Andrade ME, de Vasconcelos Generoso S, Mendes Miranda SE, Dos Reis DC, Lacerda Leocádio PC, et al. Conjugated linoleic acid prevents damage caused by intestinal mucositis induced by 5-fluorouracil in an experimental model. *Biomed Pharmacother*. 2018 Jul;103:1567-1576.
- 50- An J , Ha EM. Combination Therapy of *Lactobacillus plantarum* Supernatant and 5-Fluorouracil Increases Chemosensitivity in Colorectal Cancer Cells. *J Microbiol Biotechnol*. 2016 Aug 28;26(8):1490-503.
- 51- Wu Y, Wang B, Xu H, Tang L, Li Y, Gong L, et al. Probiotic *Bacillus Attenuates* Oxidative Stress- Induced Intestinal Injury via p38-Mediated Autophagy. *Front. Microbiol*.2019; 10:2185.
- 52- De Ávila PHM, de Ávila RI, Dos Santos Filho EX, Cunha Bastos CC, Batista AC, Mendonça EF, et al. Mucoadhesive formulation of *Bidens pilosa* L. (Asteraceae) reduces intestinal injury from 5-fluorouracil-induced mucositis in mice. *Toxicol Rep*. 2015;2:563-573.
- 53- Duncan M, Grant G. Oral and intestinal mucositis-causes and possible treatments. *Aliment. Pharmacol. Ther*. 2003; 18: 853-874.
- 54- Dahlgren D, Sjöblom M, Hellström PM, Lennernäs H. Chemotherapeutics-Induced Intestinal Mucositis: Pathophysiology and Potential Treatm

**To cite this article:** Nehal F. Shaheen, Hend R. Mousa. Intestinal Mucositis Induced by 5-Fluorouracil and the Possible Protective Effect of Probiotics Containing *Lactobacillus* in Adult Male Albino Rats: Histological and Immunohistochemical Study. *BMFJ* XXX, DOI: 10.21608/bmfj.2022.153141.1630